



**PATIENT**

Scratch Efland

**SPECIES**

Canine

**BREED**

Mixed

**SEX**

MN

**AGE**

10 years

**WEIGHT**

88 #

**INTERPRETED BY**

Remo Lobetti, BVSc,  
MMedVet (Med), PhD,  
Dipl. ECVIM

**IMAGING PERFORMED BY**

Lara Wiseman, DVM

**HOSPITAL NAME**

Boca Midtowne Animal  
Hospital

**REFERRING VET**

Dr Boazman

**INVOICE**

303393

**DATE**

9/14/22

**PRESENTING CLINICAL SIGNS**

History: Lethargy, inappetence.

Physical Examination: Bruising, pyrexia.

Urinalysis: Culture pending.

CBC: Anemia, thrombocytopenia.

Serum Biochemistry: N/A.

Radiographic Findings: Possible mass cranial abdomen.

**ULTRASONOGRAPHIC EXAMINATION OF THE ABDOMEN**

**Urinary System**

Full urinary bladder with a normal thickness and echogenic appearance of the wall. Normal anechoic urine with no sediment or uroliths evident.

Normal trigone area, proximal urethra, and iliac blood vessels.

Normal iliac lymph nodes. Ureters not visualized.

Normal renal size (left 6.9 cm, right 7.9 cm) with increased echogenic appearance, some loss of cortico-medullary differentiation, and normal pelvis, and capsule.

**Reproductive System**

Small hypoechoic prostate (1.2 cm).

**Adrenal Glands**

Normal shape, echogenic appearance, position, and size. Left 0.45 cm, right 0.4 cm.

**Spleen**

Enlarged with a mottled echogenic appearance and an irregular capsule. Multiple mottled echogenic parenchymal nodules (3.5 x 3.7 cm, 1.4 x 1.9 cm) with resultant bulging of the capsule. FNA taken with no obvious post-aspirate hemorrhage.

**Liver**

Normal size with mottled echogenic and nodular appearance, some loss of portal markings, and regular curvilinear capsule. Nodules are hypoechoic, parenchymal, and of varying sizes (up to 0.9 cm). No masses evident. Small gall bladder containing normal anechoic bile. Normal thickness and appearance of the gall bladder wall. Normal bile duct (0.2 cm).



**PATIENT**

Scratch Efland

**SPECIES**

Canine

**BREED**

Mixed

**SEX**

MN

**AGE**

10 years

**WEIGHT**

88 #

**INTERPRETED BY**

Remo Lobetti, BVSc,  
MMedVet (Med), PhD,  
Dipl. ECVIM

**IMAGING PERFORMED BY**

Lara Wiseman, DVM

**HOSPITAL NAME**

Boca Midtowne Animal  
Hospital

**REFERRING VET**

Dr Boazman

**INVOICE**

303393

**DATE**

9/14/22

**Gastrointestinal**

Normal appearance of the gastro-esophageal junction, stomach, duodenum, small intestine, ileo-cecal junction, and colon with no loss of layering, normal wall thickness (stomach 0.34 cm, duodenum 0.39 cm) and peristaltic activity, and no distension of the lumen.

**Pancreas**

Normal size (right 1.2 cm, left 1.6 cm) and echogenic appearance. Regular capsule. Normal echogenic appearance of the mesentery and fat surrounding the pancreas.

**Free Abdomen**

Mo mesenteric lymphadenomegaly.

No ascites.

Hypoechoic mottled echogenic irregular mass (3.9 x 3.1cm) caudal and lateral to the left kidney with a hyperechoic appearance of the surrounding mesentery. FNA taken with no obvious post-aspirate hemorrhage.

**ULTRASONOGRAPHIC FINDINGS**

Primary findings:

- Abdominal mass.
- Nodular hepatopathy.
- Nodular splenic pathology.

Secondary findings:

- Age-related renal changes.

**INTERPRETATION OF THE FINDINGS & FURTHER RECOMMENDATIONS**

Etiologies for the abdominal mass would be granuloma, organized hematoma, organized abscess, and neoplasia.

Etiologies for the liver would be reactive, hyperplasia, nodular hyperplasia, chronic hepatitis, and infiltrative neoplasia.

Etiologies for the spleen would be hyperplasia, granulomatous disease, splenitis, and infiltrative neoplasia.

Further assessment/therapy needs to be based on the pending FNA cytology results.



**PATIENT**

Scratch Efland

**IMAGES**

**Mass**

**SPECIES**

Canine

**BREED**

Mixed

**SEX**

MN

**AGE**

10 years

**WEIGHT**

88 #

**INTERPRETED BY**

Remo Lobetti, BVSc,  
MMedVet (Med), PhD,  
Dipl. ECVIM

**IMAGING PERFORMED BY**

Lara Wiseman, DVM

**HOSPITAL NAME**

Boca Midtowne Animal  
Hospital

**REFERRING VET**

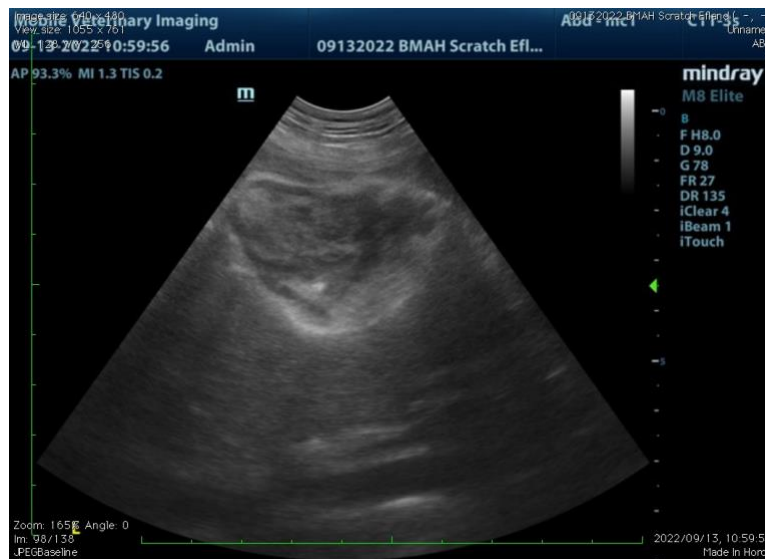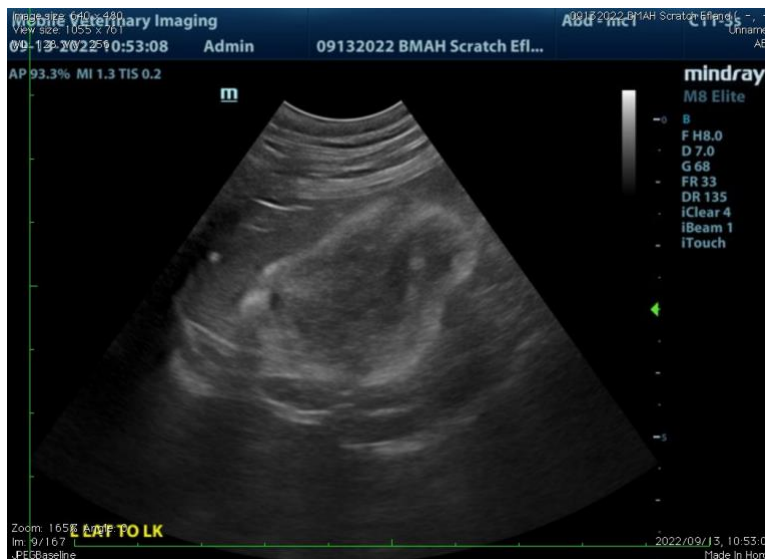Dr Boazman

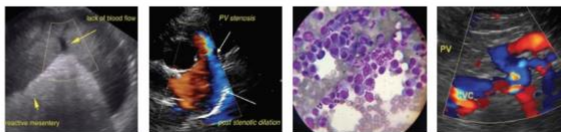
**INVOICE**

303393

**DATE**

9/14/22





**PATIENT**

Scratch Efland

**SPECIES**

Canine

**BREED**

Mixed

**SEX**

MN

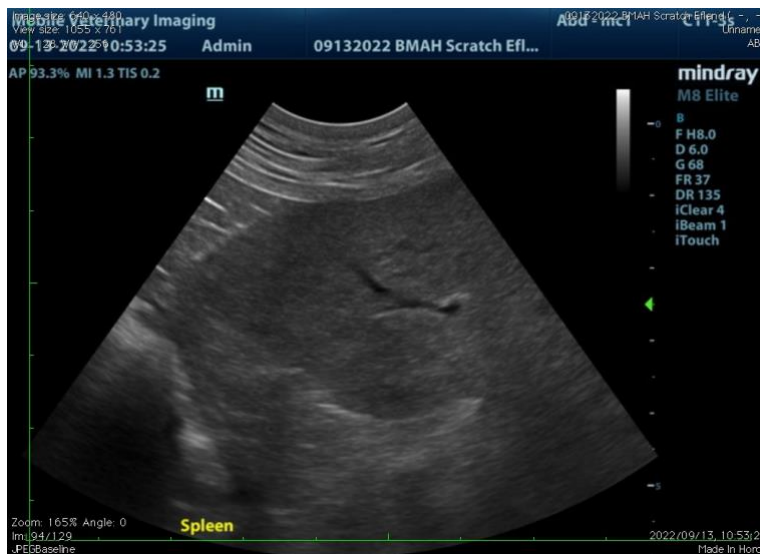**AGE**

10 years

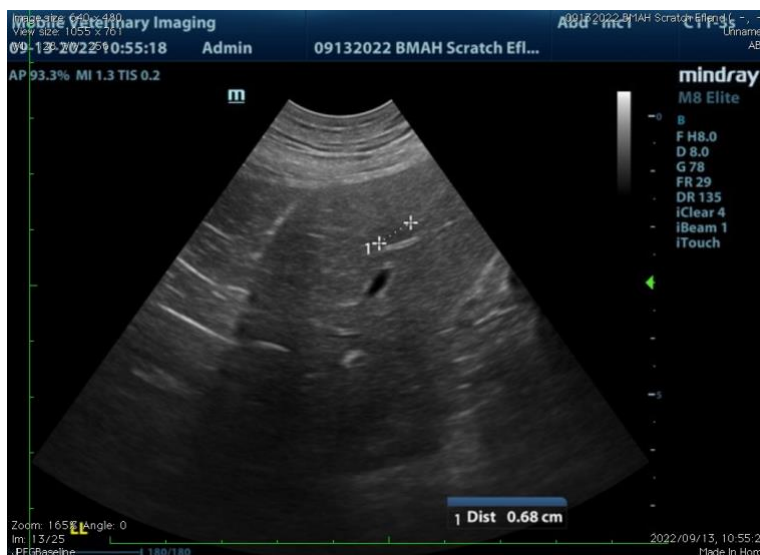**WEIGHT**

88 #

**Spleen**



**Liver**



**INTERPRETED BY**

Remo Lobetti, BVSc, MMedVet (Med), PhD, Dipl. ECVIM

**IMAGING PERFORMED BY**

Lara Wiseman, DVM

**HOSPITAL NAME**

Boca Midtowne Animal Hospital

**REFERRING VET**

Dr Boazman

**INVOICE**

303393

**DATE**

9/14/22

The information and recommendations provided are based on the images presented by the referring veterinarian. No evaluation can be communicated regarding pathology that was not visible in the image/video clips provided.

Thank you for this referral. If the clinical or image interpretation does not parallel your findings or if I can be of any further assistance please contact me.

**Remo Lobetti**, BVSc, MMedVet (Med), PhD, Dipl. ECVIM (Internal Medicine)  
rlobetti@mweb.co.za